

EVALUATION OF THE EFFECT OF A NOVEL BI-MINERAL COMPLEX ON PHOTOEXPOSED PERIORBITAL SKIN

Toni F Miller, PhD
Essex Testing Clinic, Inc.
Verona, NJ

R Sonia Batra, MD
City of Hope
Duarte, CA

Jose Ramirez, PhD
JR Chemical
Milford, CT

INTRODUCTION

The elasticity of the skin is attributable to elastic fibers that can stretch and then recoil. The elastic fibers contain elastin—a large protein synthesized by dermal fibroblasts that forms spiral filaments comparable to springs. The spiral filaments are crosslinked together and, when the skin is stretched, this crosslinking enables the spiral filaments to spring back to their original positions. Aging and photoaging can reduce skin elasticity as a result of degradation of elastic fibers by elastolytic proteinases and impaired remodeling of the fibers. Since adult dermal fibroblasts lose their ability to correctly synthesize and deposit elastin, they are unable to replace damaged elastic fibers. The resultant loss of elasticity can be seen clinically as wrinkling, laxity, looseness, roughness, and crepiness of the skin.

Some coordination minerals, such as copper and zinc, are thought to act directly on fibroblasts to increase the mRNA for elastin and so offer the potential for enhancing the elasticity of the skin. Previous clinical studies have demonstrated that topical applications of a novel bi-mineral complex can increase both the number and density of dermal fibroblasts and the deposition of elastic fibers in photoprotected skin.¹ To further explore the clinical potential of this bi-mineral complex, a study has been performed to evaluate its effect on photoexposed periorbital skin with regard to elasticity, moisturization, and hyperkinetic lines (crow's feet).

METHODS

Key inclusion criteria

- Female healthy volunteers, aged 45-69 years
- Moderate to deep periorbital lines that were evident on photographs
- Willing to refrain from using any product on the face other than study products
- No participation in other clinical studies in preceding 14 days

Key exclusion criteria

- Active or chronic skin allergies
- Type I diabetes
- History of acute or chronic disease that might interfere with, or increase the risk of, study participation

- Skin cancer treatment in preceding 12 months
- Damaged skin near study areas (eg, from sunburn, tattoos, scars)
- Any medical procedure (eg, laser resurfacing, chemical peels, plastic surgery) to study areas in preceding 12 months

- Use of topical retinoids or related agents for the treatment of acne or photoaging in the preceding 6 months

- Pregnant or nursing

Washout periods

- At least 3 days for all facial products other than those provided by the sponsor.

Treatment regimen

- Subjects applied the novel bi-mineral complex to the area around their eyes, twice daily for 8 weeks.
- One pump (~ 0.25 g) of the product was dispensed onto the fingers and applied to the right periorbital area. Another pump of the product was applied to the left periorbital area. Subjects were instructed to feather excess product outward to the cheeks and forehead.
- Before applying the bi-mineral complex, subjects washed their face with a gentle cleanser and then dried their skin.
- Subjects were instructed to stop using all other facial products.

Outcome measures

- The elasticity of the skin was evaluated by assessing the speed of its recoil after being pulled by vacuum into the aperture of a Cutometer® probe. For each evaluation the probe was placed on the skin near the crow's feet area and the skin pulled by vacuum for approximately 2-10 seconds before being released.
- The moisture content of the skin was evaluated by assessing the dielectric constant in the stratum corneum using a Corneometer®. The higher the dielectric constant, the more hydrated the stratum corneum.
- The number of wrinkles was assessed as the total number of features detected in 10 subareas (parallel bands) on silicone replicas of the periorbital skin.
- Subjects completed questionnaires at least every 2 weeks that assessed the following (Table 1):
 - Severity of their periorbital lines at rest
 - Satisfaction with improvement in the appearance of their periorbital fine lines and wrinkles
 - Satisfaction with improvement in the *texture* of their periorbital skin (ie, roughness/crepiness)
 - Appearance of their skin after using the bi-mineral complex compared with after using other products in the past.
- At the end of the study (ie, week 9), subjects viewed their pre-treatment

TABLE 1 Scales for efficacy outcome measures.

Grade	Severity of periorbital lines at rest	Satisfaction with improvement in appearance of periorbital fine lines and wrinkles	Satisfaction with improvement in <i>texture</i> of periorbital skin (roughness/crepiness)	Appearance compared with appearance after using other products in the past	Overall appearance of periorbital skin at end of study	Laxity/looseness of periorbital skin at end of study	Roughness/crepiness of periorbital skin at end of study
0	None	—	—	—	—	None	None
1	Mild/barely noticeable	Very satisfied	Very satisfied	Much better	Excellent	Mild/barely noticeable	Mild/barely noticeable
2	Moderate/easily noticeable	Somewhat satisfied	Somewhat satisfied	Somewhat better	Very good	Moderate/easily noticeable	Moderate/easily noticeable
3	Severe/prominent	Neutral	Neutral	No change	Good	Severe/prominent	Severe/prominent
4	—	Somewhat dissatisfied	Somewhat dissatisfied	Somewhat worse	Fair	—	—
5	—	Not at all satisfied	Not at all satisfied	Much worse	Poor	—	—

and post-treatment photographs and evaluated their periorbital skin in terms of the following (Table 1):

- Overall appearance
- Laxity/looseness
- Roughness/crepiness.

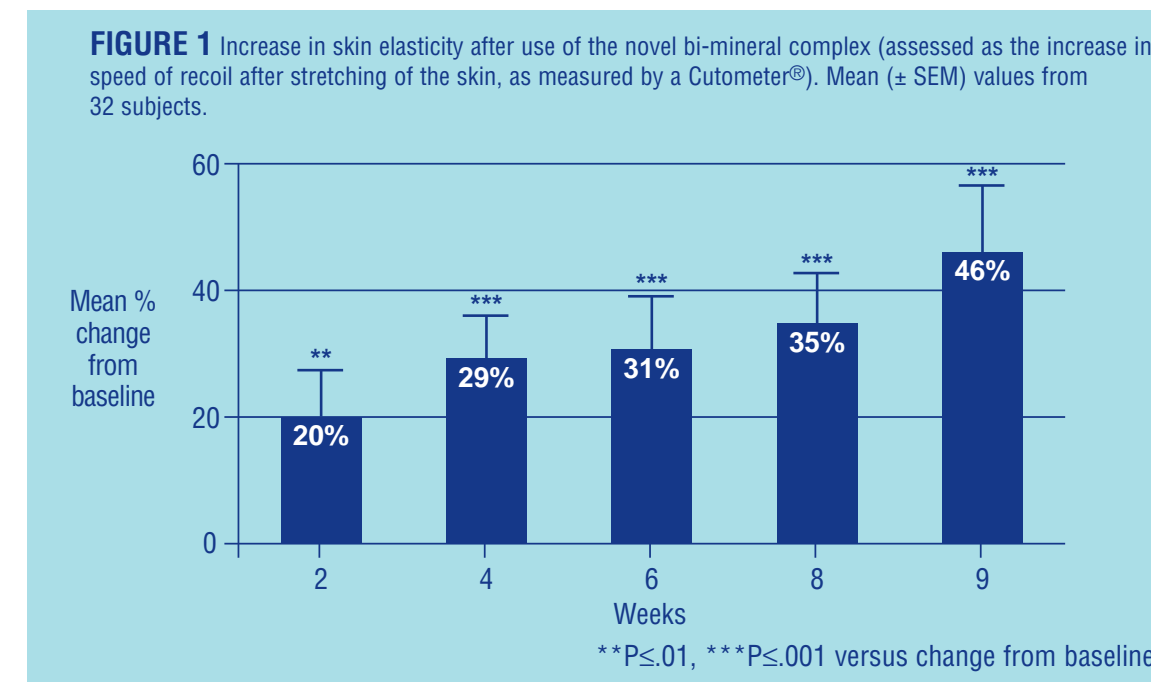
RESULTS

Subjects

- 33 subjects were enrolled, of whom 32 (97%) completed. (One discontinued as a result of relocating.)

Efficacy

- Twice-daily applications of the bi-mineral complex resulted in:
 - Significantly enhanced elasticity as early as week 2 ($P \leq .01$) through week 9 ($P \leq .0001$)—elasticity increased with each successive visit with a peak 46% improvement relative to baseline at week 9 (Figure 1)



- Significantly enhanced moisturization from weeks 2-6, by up to 7% relative to baseline (Figure 2)
- A significant reduction in the number of wrinkles evident on silicone replicas, peaking at 16% at week 9 (Figure 3)
- Visible improvements in periorbital lines (Figure 4).

- Subject ratings at week 9 (ie, 1 week post-treatment) revealed that:

- 47% of subjects considered the severity of their periorbital lines to be none or mild/barely noticeable (Figure 5)
- 80% were very satisfied or somewhat satisfied with the improvement in the appearance of their periorbital fine lines and wrinkles (Figure 6)
- 73% were very satisfied or somewhat satisfied with the improvement in the *texture* of their periorbital skin (Figure 7)
- 71% considered their appearance to be better after using the bi-mineral complex than after using other products in the past (Figure 8).

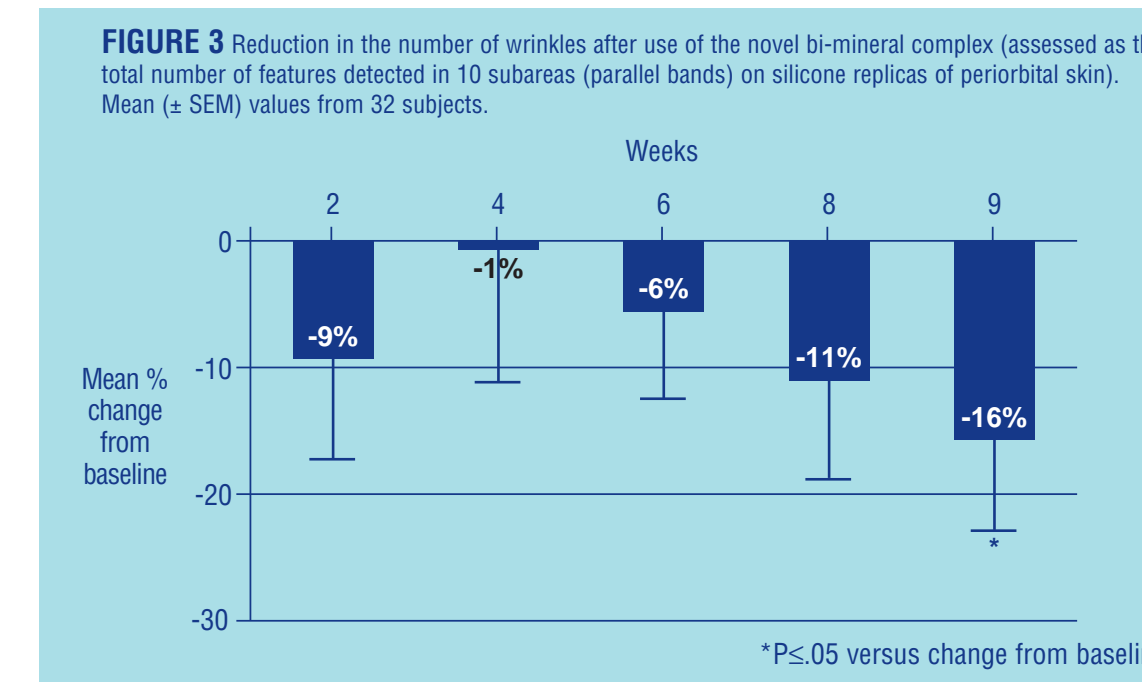
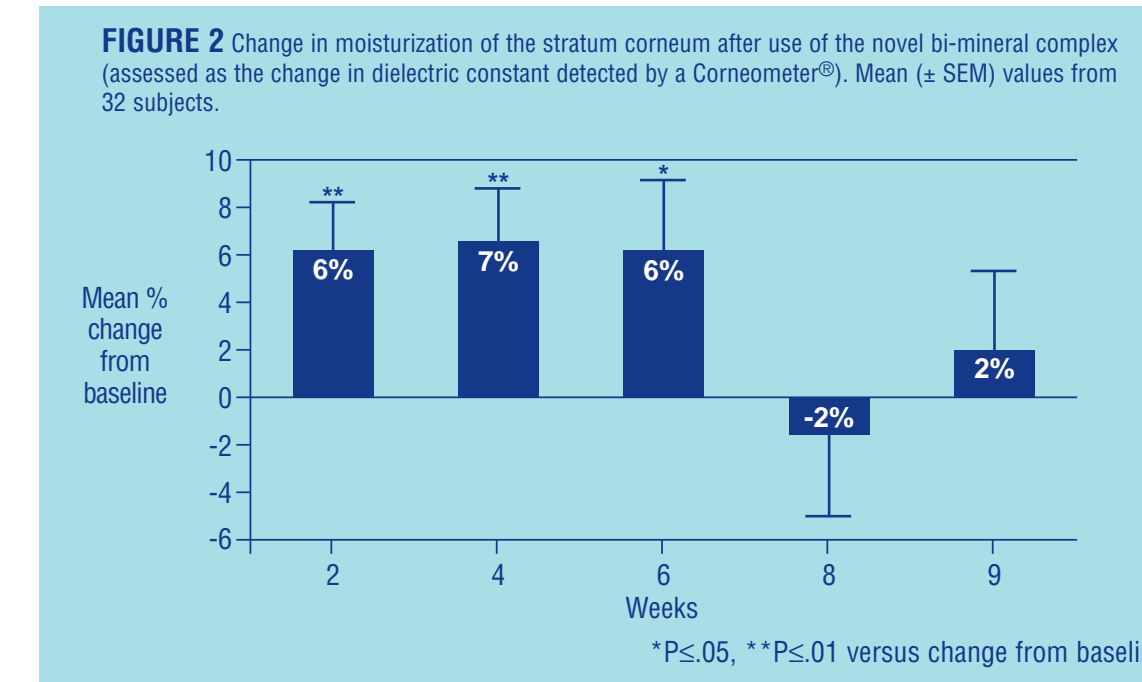
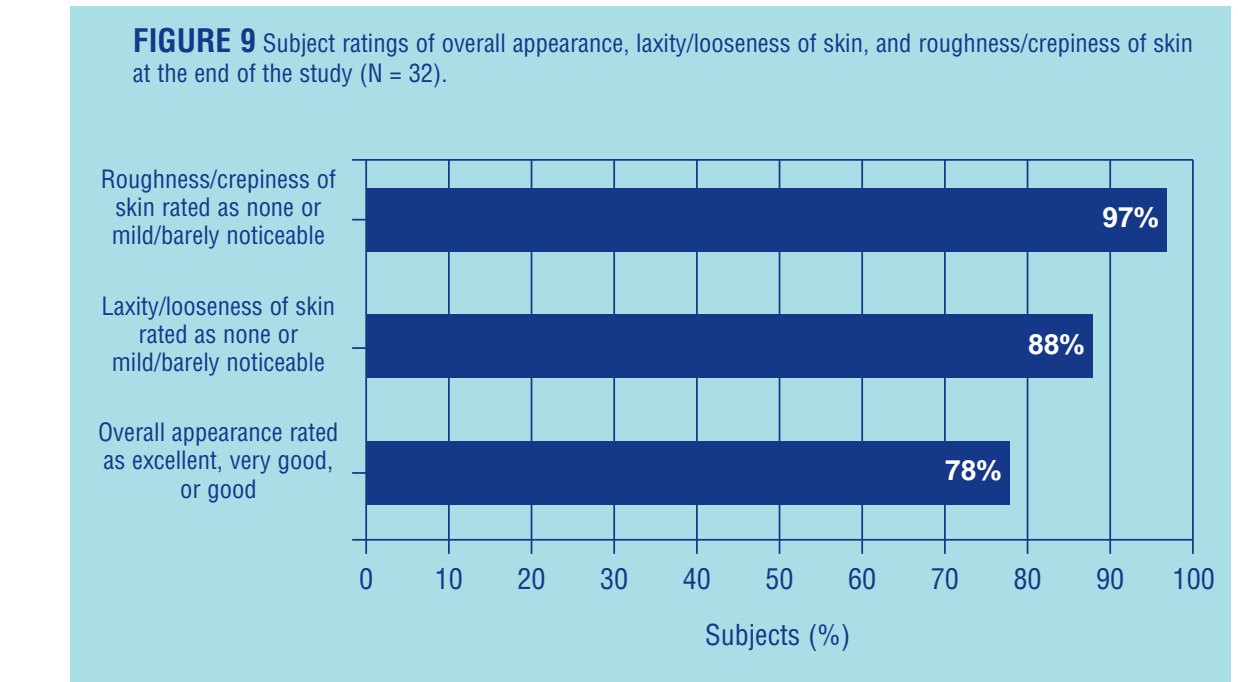
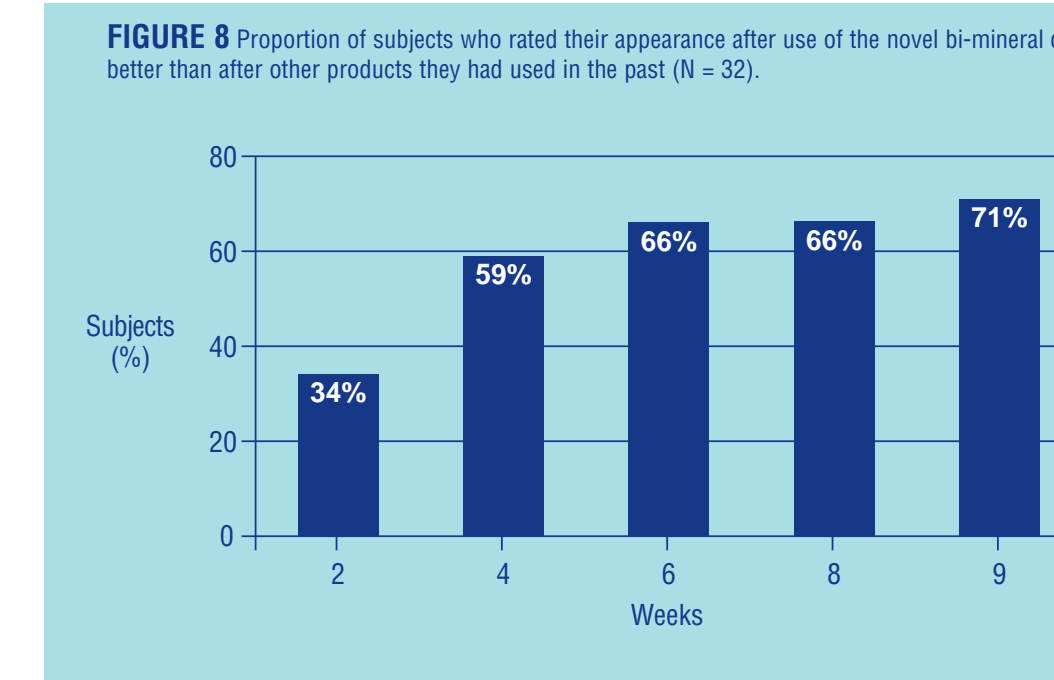
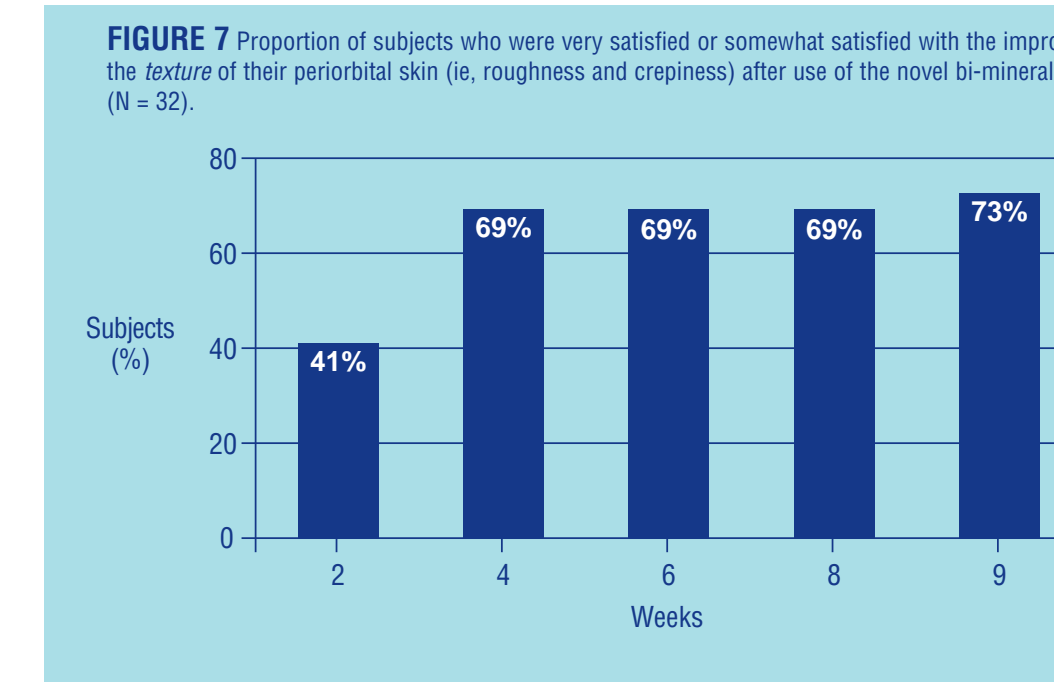
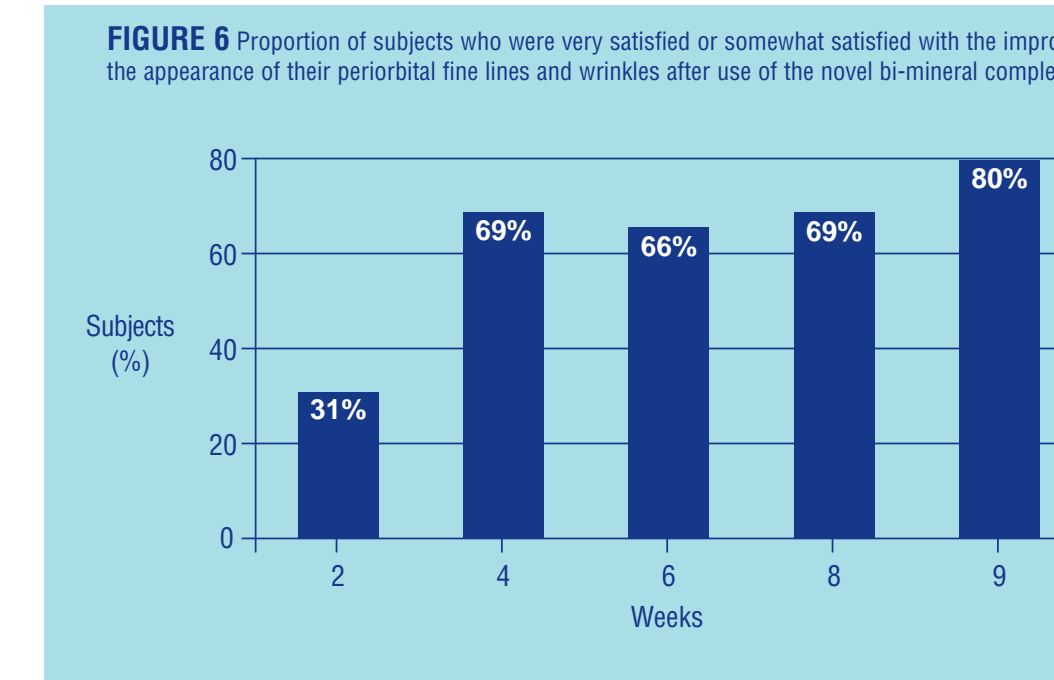
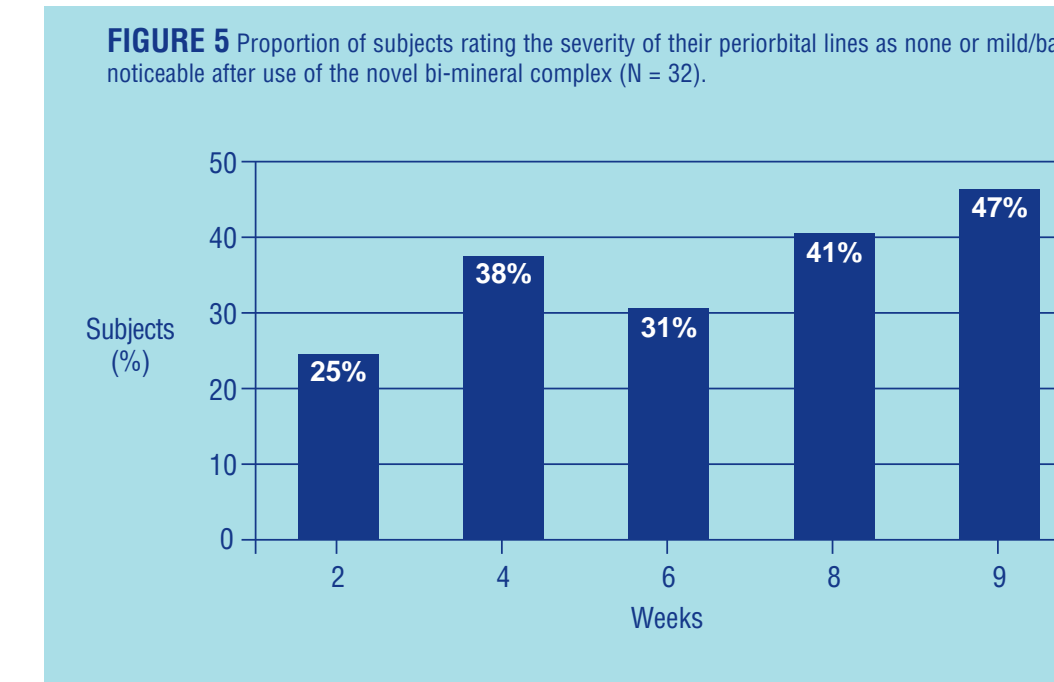
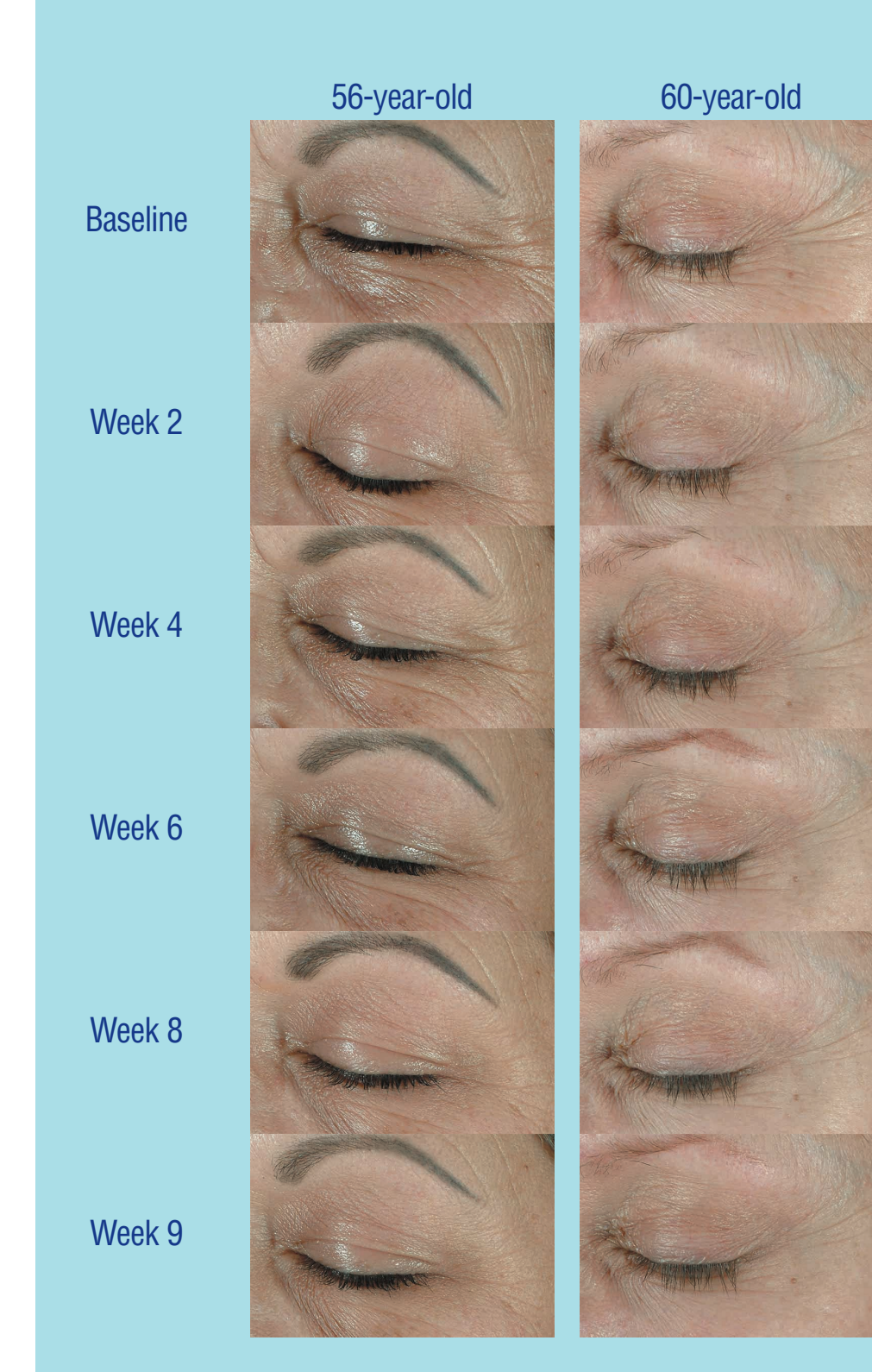


FIGURE 4 Visible improvements in appearance of periorbital lines.



- There was no regression in the values for any of the above-mentioned parameters between week 8 (when applications of the product ceased) and week 9, indicating that the effects of the product did not regress in the week following its discontinuation.
- Subject ratings from the end-of-study questionnaire showed that:
 - 78% of subjects considered the overall appearance of their periorbital skin to be excellent, very good, or good (Figure 9)
 - 88% considered the laxity/looseness of their periorbital skin to be none or mild/barely noticeable (Figure 9)
 - 97% considered the roughness/crepiness of their periorbital skin to be none or mild/barely noticeable (Figure 9).

Tolerability

- No adverse events were reported.

CONCLUSIONS

The novel bi-mineral complex was effective in improving the elasticity of photoexposed skin and visibly reducing periorbital lines. A significant increase in elasticity was achieved within only 2 weeks and elasticity continued to increase with each successive visit. Importantly, the increase in elasticity was independent of moisturization (elasticity increased by up to 46% relative to baseline, whereas moisturization increased no more than 7%)—indicating that the effects of the bi-mineral complex were not simply the consequence of increased hydration.

Use of the bi-mineral complex was also associated with high levels of subject satisfaction, with 80% of the subjects being very satisfied or somewhat satisfied with the improvement in the appearance of their periorbital fine lines and wrinkles.

REFERENCES

- Data on file. OMP, Inc., 2006.

DISCLOSURES

Supported by OMP, Inc., Long Beach, CA.